



Genetic linkage analysis of oral lichen planus in a Chinese family

Z. Wang¹, H. Yao¹, B. Cui², G. Ning² and G.Y. Tang¹

¹Shanghai Key Laboratory of Stomatology, Department of Oral Medicine, Ninth People's Hospital, Shanghai Jiao Tong University School of Medicine, Shanghai, P.R. China

²Shanghai Clinical Center for Endocrine and Metabolic Diseases, Shanghai Institute of Endocrine and Metabolic Diseases, Ruijin Hospital, Shanghai JiaoTong University School of Medicine, P.R. China

Corresponding author: G.Y. Tang
E-mail: tanggysh@gmail.com

Genet. Mol. Res. 10 (3): 1427-1433 (2011)
Received November 4, 2010
Accepted January 1, 2011
Published July 19, 2011
DOI 10.4238/vol10-3gmr1137

ABSTRACT. Oral lichen planus (OLP) is a common oral inflammatory disease affecting about 1-2% of the general adult population. As with European families who are diagnosed with OLP, the Chinese family who we studied was diagnosed with a severe form of oral reticular and erosive lesions; moreover, two of the five affected individuals developed oral cancer at an early age. A whole-genome genotyping scan with linkage analysis was performed using the 10K SNP array to investigate the genetic susceptibility of the Chinese family to OLP, which revealed one maximal nonparametric LOD score of 2.32 ($P = 0.0156$) for SNP marker rs2372736, defined at the chromosome 3p14-3q13 region encompassing 19 SNPs. Blood samples were obtained from 10 members of the family, which included the grandmother, father and mother, and the children altogether. The grandfather is dead, but the family members remembered he also suffered from the same disease. Chromosome 3p14-3q13 was identified as the candidate gene region for OLP; this information provides a foundation for further identification of the gene responsible for OLP.

Key words: Oral lichen planus (OLP); Linkage analysis; Chromosome 3

INTRODUCTION

Oral lichen planus (OLP) is a chronic inflammatory disease that affects the oral cavity; it is more often found in the buccal mucosa and is frequently observed on the tongue and gingiva. Lesions are rarely found on the palate, and blisters may or may not be present (Jungell, 1991; Silverman Jr. and Bahl, 1997; Chaiyarit et al., 1999). OLP is one of the most common oral mucosa diseases and affects approximately 1-2% of the general adult population (Axéll and Rundquist, 1987). Previous studies suggested that OLP is a T cell-mediated autoimmune disease in which autotoxic CD8+ T cells trigger apoptosis of oral epithelial cells (Sugerman et al., 2000, 2002). High serum and salivary levels of the cytokine tumor necrosis factor (TNF) have also been detected in OLP patients (Sklavounou-Andrikopoulou et al., 2004). Thalidomide, which is known to suppress TNF production, has been used to successfully treat OLP (Camisa and Popovsky, 2000; Petropoulou et al., 2006), and this may implicate TNF in the pathogenesis of OLP. The latest research evaluated the presence of the angiogenic phenomenon in a series of biopsies of specimens from OLP patients, and the immunohistochemical results showed significant neoangiogenesis in OLP (Scardina et al., 2009). However, the precise cause of OLP is unknown.

Erasmus Wilson initially described OLP in 1869 (Wilson, 1869). OLP is diagnosed in any one of the following clinical forms: atrophic, bullous, erosive, papular, plaque-like, or reticular, with the reticular form being the most common. The condition is most often seen in middle-aged patients; it affects women more than men, and rarely children (Vincent et al., 1990; Lozada-Nur and Miranda, 1997). In the family studied, the affected mothers had more serious symptomatic, extensive, and severe erosive lesions; in addition, the age of onset was early (Bermejo-Fenoll and Lopez-Jornet, 2006).

The Chinese family studied was affected with a severe form of oral reticular and erosive lesions, and 2 of the 5 affected individuals had already developed oral cancer at an early age. We performed genome-wide single nucleotide polymorphism (SNP) genotyping to screen for a disease locus. Finally, we identified a novel candidate gene region of chromosome 3p14-3q13.

SUBJECTS AND METHODS

Subjects

A three-generation OLP family was identified at Shanghai Ninth People's Hospital in China in 1993. Of the 13 living members, 5 were affected as shown by the family tree in Figure 1. All participating family members received thorough clinical examinations. OLP was diagnosed according to the clinical manifestations and histopathological criteria of the World Health Organization. Symptoms were bilateral, more or less symmetrical lesions, and a lace-like network of slightly raised gray-white lines (reticular pattern). Erosive, atrophic, bullous, and plaque-type lesions were only accepted as a subtype in the presence of reticular lesions elsewhere in the oral mucosa. Histopathological criteria were the presence of a well-defined band-like zone of cellular infiltration that was confined to the superficial part of the connective tissue, consisting mainly of lymphocytes, signs of "liquefaction degeneration" in the basal cell layer, and the absence of epithelial dysplasia (van der Meij et al., 2007). Informed consent was obtained and blood samples were collected from participating family members. This study

was approved by the Ethics Committee of the Ninth People's Hospital, School of Medicine, Shanghai Jiao Tong University.

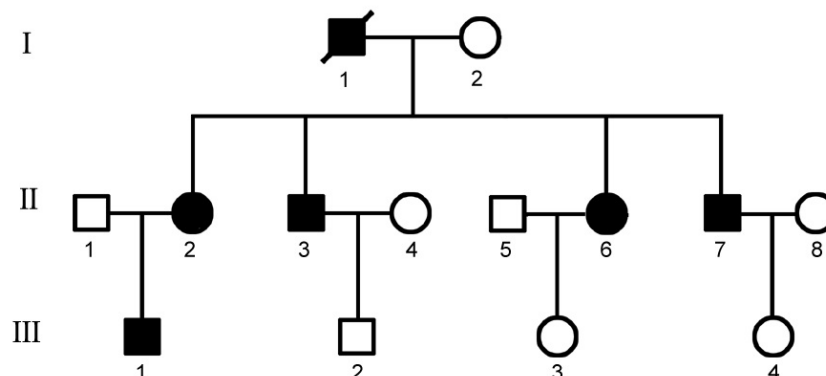


Figure 1. The pedigree of oral lichen planus (OLP). Two generations of this family were affected by OLP with severe oral reticular and erosive lesions. I-1 is dead, but the family members remembered that he also suffered from the same disease. The disorder was transmitted from parents to offspring. Individuals of II-4, II-5 and II-8 did not consent to donating blood for linkage analysis.

Genotyping

Genomic DNA was extracted from peripheral blood by using the QIAGEN DNA mini kit (Qiagen, Hilden, Germany) according to manufacturer instructions. SNPs were chosen as the marker for genome-wide linkage scans. The Affymetrix GeneChip human mapping 10K SNP Array was used to genotype 10 samples with the standard protocol recommended by the manufacturer (Affymetrix, USA). Two hundred and fifty nanograms of genomic DNA was digested with *Xba*I and ligated to adapters that recognized the cohesive 4-bp overhangs. A generic primer that recognized the adapter sequence was then used to amplify the adapter-ligated fragments by polymerase chain reaction (PCR). The amplified DNA was then fragmented, labeled and hybridized to the array. The Affymetrix GeneChip Operating Software (GCOS) collected and extracted feature data from the scanner, which was then analyzed with the Affymetrix GeneChip Genotyping Analysis Software (GTYPE).

Linkage mapping analysis

In linkage and haplotype analyses, the genome-wide array SNP data were analyzed by the Genespring GT software package (Agilent Technologies, USA), including inheritance checking, haplotype inference, and data analysis. Because of uncertainties regarding the inheritance of OLP disease, nonparametric linkage analysis was carried out and yielded a maximum nonparametric logarithm of the odds (LOD) score. Multipoint haplotype-base linkage analysis was also conducted on the whole genome. Each array has 11,555 SNPs and the median physical distance between SNPs was approximately 105 kb. The data analyzed were classified by chromosome and sorted based on the physical position of the SNPs. This program utilizes the SNP position information from dbSNP build 124 and Biotechnology Information build 35v1 of the human genome.

RESULTS

Clinical characteristics

The main clinical characteristics of the OLP patients studied are shown in Table 1. There is a wide range of onset from 33 to 55 years of age, an equal distribution between males and females, and no other skin or mucosa membrane disorder. The onset of OLP in oral reticular lesion form is subtle, and the patients with II-2 and III-1 were unaware of their condition. However, patients with erosive lesions in the initial stage suffered from obvious pain. Figure 2 shows the clinical image of oral reticular and erosive lesions of OLP (A-C) and the histology section (D). Some of the family members were also affected with other systemic disorders such as type B hepatitis, anemia, and superficial gastritis. It is emphatically pointed out that the II-3 and II-6 patients developed oral cancer.

Table 1. Clinical summary of familial oral lichen planus cases.

Case	Gender	Age (years)	Evolution time	Predominant form	Sites	Medical history	Diagnosis	Psychological factor
II-2	F	60	Unknown	Reticular	Buccal, gingiva	None	Clinical, pathological	No
II-3	M	58	16 years	Erosive, reticular	Buccal	None	Clinical, pathological	Yes
II-6	F	55	3 years	Erosive, reticular	Tongue, buccal	Anemia, gastritis	Clinical, pathological	Yes
II-7	M	53	2 years	Erosive, reticular	Buccal, gingiva, tongue	Type B hepatitis	Clinical, pathological	Yes
III-1	M	35	Unknown	Reticular	Buccal, gingiva	None	Clinical, pathological	No

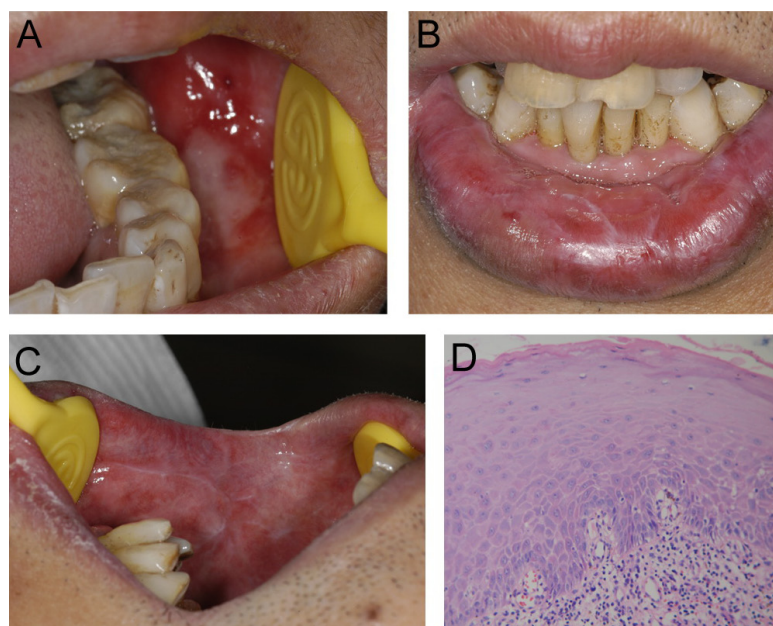


Figure 2. The clinical images of oral lichen planus and histology section. **A.** Clinical image of the erosive lesion located in the buccal mucosa. **B.** Labial reticular lesion. **C.** Reticular lesion in the buccal mucosa. **D.** Histology section showing areas of epithelial atrophy, and a layered, marked lymphocyte infiltration in the lamina propria (hematoxylin and eosin stain, 100X).

Genetic linkage analysis

A whole-genome scan with the GeneChip Human Mapping 10K Array was performed on 10 (5 affected, 2 unaffected, and 3 unknown) individuals from the OLP family to locate the locus of the disease. The results yielded an average call rate of 98.97% and an average signal detection rate of 99.66%. After filtering for non-Mendelian inheritance, the rest of the SNP genotypes was used for linkage analysis. Genome-wide genetic linkage analysis with the Genespring GT software revealed one maximal nonparametric LOD score of 2.32 ($P = 0.0156$) for SNP marker rs2372736 (physical map position Chr.3: 81090355 bp), defined at the chromosome 3p14-3q13 region encompassing 19 SNPs (Table 2).

Table 2. Oral lichen planus loci in the Chinese family mapped by linkage analysis to chromosome 3p14-3q13 region.

SNP marker	Physical position	NPL score	NPL P value
rs2372736	Chr3:81,090,355	2.32	0.0156
rs1400410	Chr3:108,613,417	2.262	0.0156
rs938431	Chr3:108,548,082	2.192	0.0156
rs1995758	Chr3:62,066,182	2.108	0.0469
rs953311	Chr3:62,066,716	1.929	0.0469
rs1384309	Chr3:84,484,209	1.929	0.0469
rs2371948	Chr3:65,337,837	1.900	0.0469
rs2134655	Chr3:115,340,891	1.875	0.0469
rs1129055	Chr3:123,321,009	1.811	0.0469
rs967331	Chr3:61,422,777	1.805	0.0469
rs2317750	Chr3:102,604,810	1.793	0.0469
rs753821	Chr3:58,589,460	1.793	0.0469
rs1915337	Chr3:110,978,719	1.777	0.0469
rs2090768	Chr3:110,978,821	1.777	0.0469
rs2004199	Chr3:56,620,906	1.747	0.0469
rs3842905	Chr3:113,839,242	1.734	0.0469
rs718007	Chr3:105,825,933	1.728	0.0469
rs1515002	Chr3:80,631,947	1.722	0.0469
rs2367106	Chr3:59,881,001	1.711	0.0469

SNP = single nucleotide polymorphism; NPL = nonparametric linkage analysis.

DISCUSSION

Our study on the Chinese family affected with OLP identified heredity as the cause for this disease, which was characterized by similar clinical symptoms, severe condition, and increased chance of developing cancer. Compared to 6 different Spanish OLP families, our Chinese familial OLP patients had similar age of onset, similar forms of lichen planus, and similar locations of the lesions in the oral cavity (Bermejo-Fenoll and Lopez-Jornet, 2006). However, the affected members were not found to show a significant difference in gender, which may be the reason for the difficulty in analyzing the gender-related differences in this small family. Moreover, the follow-up observation disclosed that 2 of the OLP patients developed oral cancer.

According to previous studies, OLP was thought to be an immune-related disease with a complex genetic background. Recently, several studies have revealed the genetic susceptibility of OLP through case-control association testing. Fourteen SNPs of genes that regulate host immune responses have been categorized for Japanese OLP patients and unrelated healthy controls. The results suggested that the TNFR2 +587 gene polymorphism may be associated

with susceptibility to OLP (Fujita et al., 2009). A series of inflammation- and immune regulation-related cytokines, such as interferon-gamma (IFN- γ) and interleukin-4 (IL-4), TNF-alpha (TNF- α) and IL-10, and IL-8, which have an important role in the pathogenesis and disease progression of OLP, have been investigated for establishing the connection to gene polymorphisms with OLP in the Chinese population. These studies have identified that genetic variants were a positive influence on disease susceptibility and on the progression of OLP (Bai et al., 2009; Liu et al., 2009; Dan et al., 2010).

Pathogenesis of complex diseases involves the integration of genetic and environmental factors over time. Case-control association testing can be used to detect the association between gene polymorphisms and the disease, to identify genetic susceptibility, and to determine the risk factors of the disease. However, a large affected and unaffected population must be used. Furthermore, it is difficult to choose and define the candidate genes. Using OLP family samples, we performed whole-genome genetic linkage analysis and identified the disease locus of chromosome 3p14-3q13 region, where one mutation may be responsible for familial OLP. This finding would also suggest that a novel gene in the chromosome 3p14-3q13 region may play a role in the pathogenesis of OLP.

ACKNOWLEDGMENTS

Research supported by grant #30872888 from the National Natural Science Foundation of China; by grant #S30206 from the Shanghai Leading Academic Discipline Project, and by grant #08DZ2271100 from the Science and Technology Commission of Shanghai.

REFERENCES

- Axéll T and Rundquist L (1987). Oral lichen planus - a demographic study. *Community Dent. Oral Epidemiol.* 15: 52-56.
- Bai J, Jiang L, Lin M, Zeng X, et al. (2009). Association of polymorphisms in the tumor necrosis factor-alpha and interleukin-10 genes with oral lichen planus: a study in a Chinese cohort with Han ethnicity. *J. Interferon Cytokine Res.* 29: 381-388.
- Bermejo-Fenoll A and Lopez-Jornet P (2006). Familial oral lichen planus: presentation of six families. *Oral Surg. Oral Med. Oral Pathol. Oral Radiol. Endod.* 102: e12-e15.
- Camisa C and Popovsky JL (2000). Effective treatment of oral erosive lichen planus with thalidomide. *Arch. Dermatol.* 136: 1442-1443.
- Chaiyavit P, Kafrawy AH, Miles DA, Zunt SL, et al. (1999). Oral lichen planus: an immunohistochemical study of heat shock proteins (HSPs) and cytokeratins (CKs) and a unifying hypothesis of pathogenesis. *J. Oral Pathol. Med.* 28: 210-215.
- Dan H, Liu W, Zhou Y, Wang J, et al. (2010). Association of interleukin-8 gene polymorphisms and haplotypes with oral lichen planus in a Chinese population. *Inflammation* 33: 76-81.
- Fujita H, Kobayashi T, Tai H, Nagata M, et al. (2009). Assessment of 14 functional gene polymorphisms in Japanese patients with oral lichen planus: a pilot case-control study. *Int. J. Oral Maxillofac. Surg.* 38: 978-983.
- Jungell P (1991). Oral lichen planus. A review. *Int. J. Oral Maxillofac. Surg.* 20: 129-135.
- Liu W, Dan H, Wang Z, Jiang L, et al. (2009). IFN-gamma and IL-4 in saliva of patients with oral lichen planus: a study in an ethnic Chinese population. *Inflammation* 32: 176-181.
- Lozada-Nur F and Miranda C (1997). Oral lichen planus: epidemiology, clinical characteristics, and associated diseases. *Semin. Cutan. Med. Surg.* 16: 273-277.
- Petropoulou H, Kontochristopoulos G, Kalogirou O, Panteri I, et al. (2006). Effective treatment of erosive lichen planus with thalidomide and topical tacrolimus. *Int. J. Dermatol.* 45: 1244-1245.
- Scardina GA, Ruggieri A, Messina P and Maresi E (2009). Angiogenesis of oral lichen planus: a possible pathogenetic mechanism. *Med. Oral Patol. Oral Cir. Bucal.* 14: e558-e562.
- Silverman S Jr and Bahl S (1997). Oral lichen planus update: clinical characteristics, treatment responses, and malignant

- transformation. *Am. J. Dent.* 10: 259-263.
- Sklavounou-Andrikopoulou A, Chrysomali E, Iakovou M, Garinis GA, et al. (2004). Elevated serum levels of the apoptosis related molecules TNF-alpha, Fas/Apo-1 and Bcl-2 in oral lichen planus. *J. Oral Pathol. Med.* 33: 386-390.
- Sugerman PB, Satterwhite K and Bigby M (2000). Autocytotoxic T-cell clones in lichen planus. *Br. J. Dermatol.* 142: 449-456.
- Sugerman PB, Savage NW, Walsh LJ, Zhao ZZ, et al. (2002). The pathogenesis of oral lichen planus. *Crit. Rev. Oral Biol. Med.* 13: 350-365.
- van der Meij EH, Mast H and van der Waal I (2007). The possible premalignant character of oral lichen planus and oral lichenoid lesions: a prospective five-year follow-up study of 192 patients. *Oral Oncol.* 43: 742-748.
- Vincent SD, Fotos PG, Baker KA and Williams TP (1990). Oral lichen planus: the clinical, historical, and therapeutic features of 100 cases. *Oral Surg. Oral Med. Oral Pathol.* 70: 165-171.
- Wilson E (1869). On lichen planus. *J. Cutan. Med. Dis. Skin.* 3: 117-132.